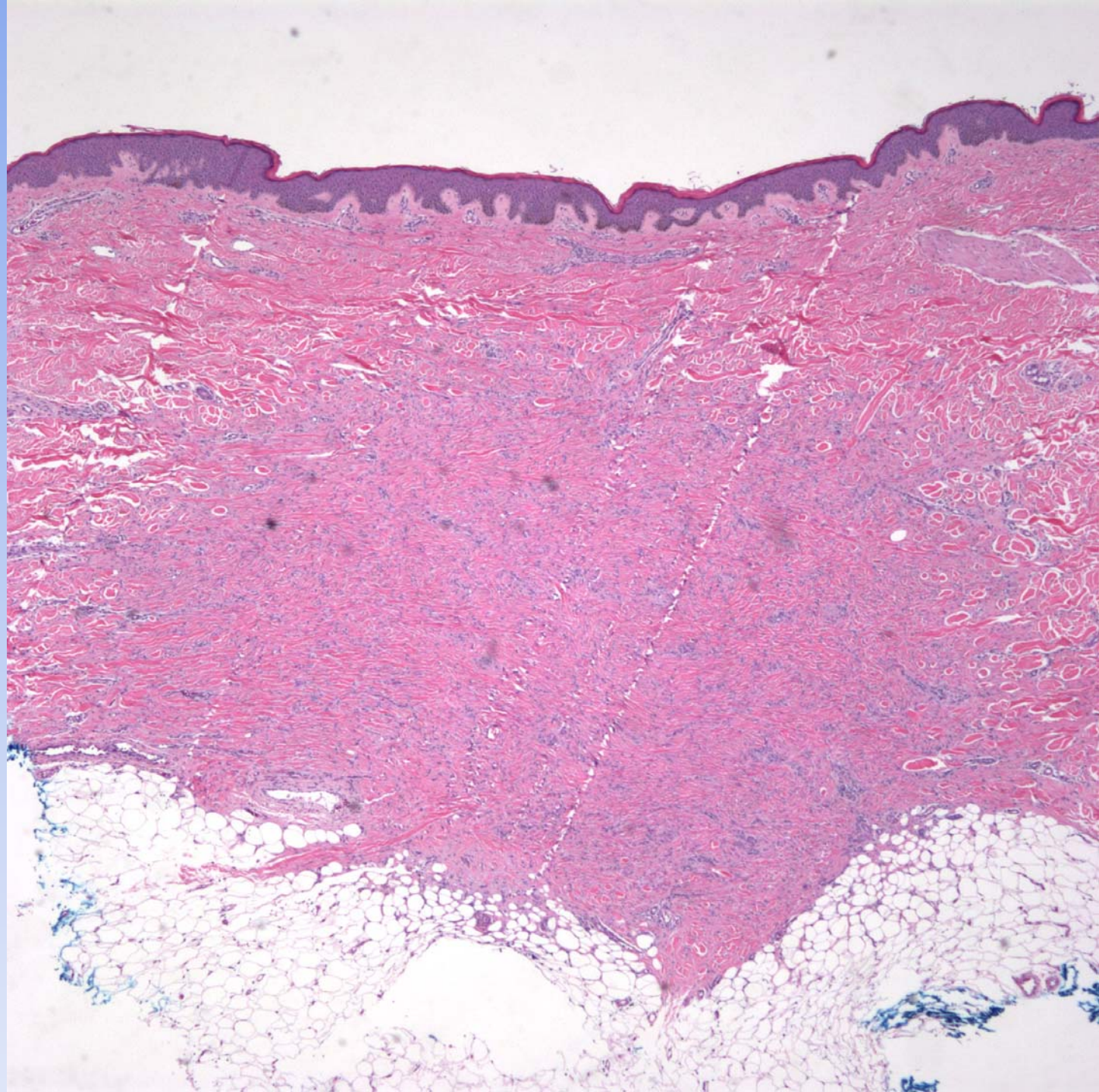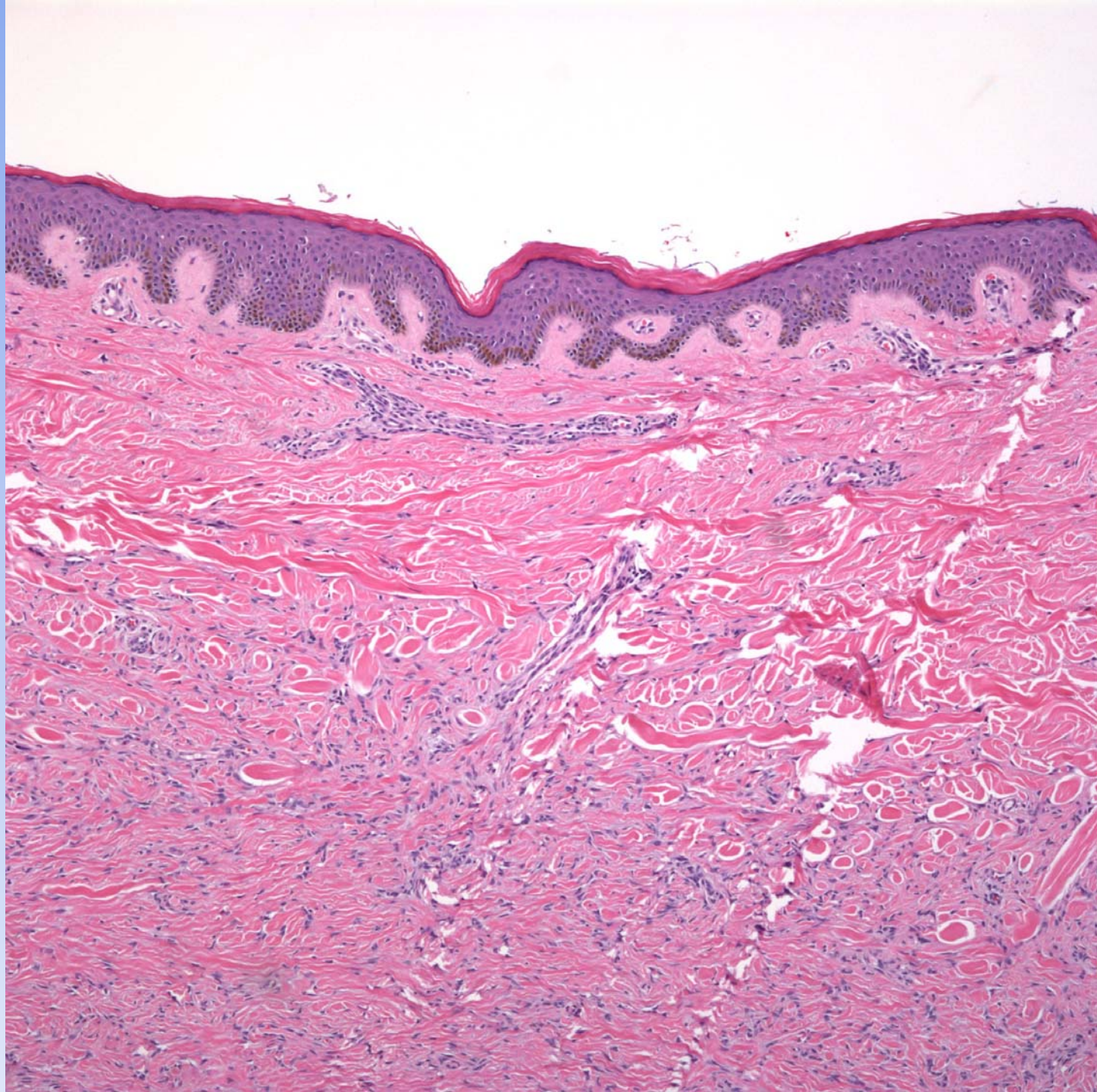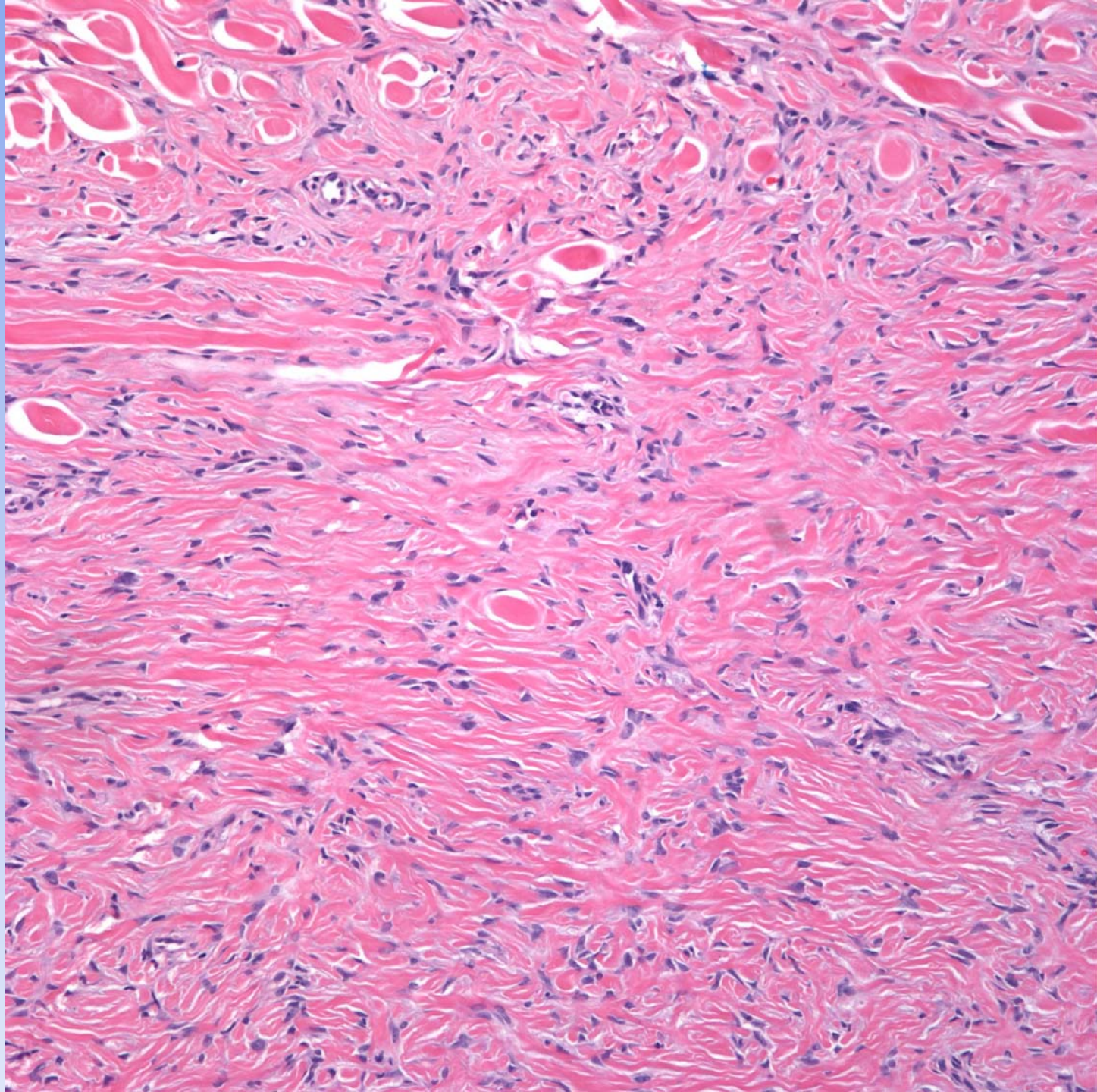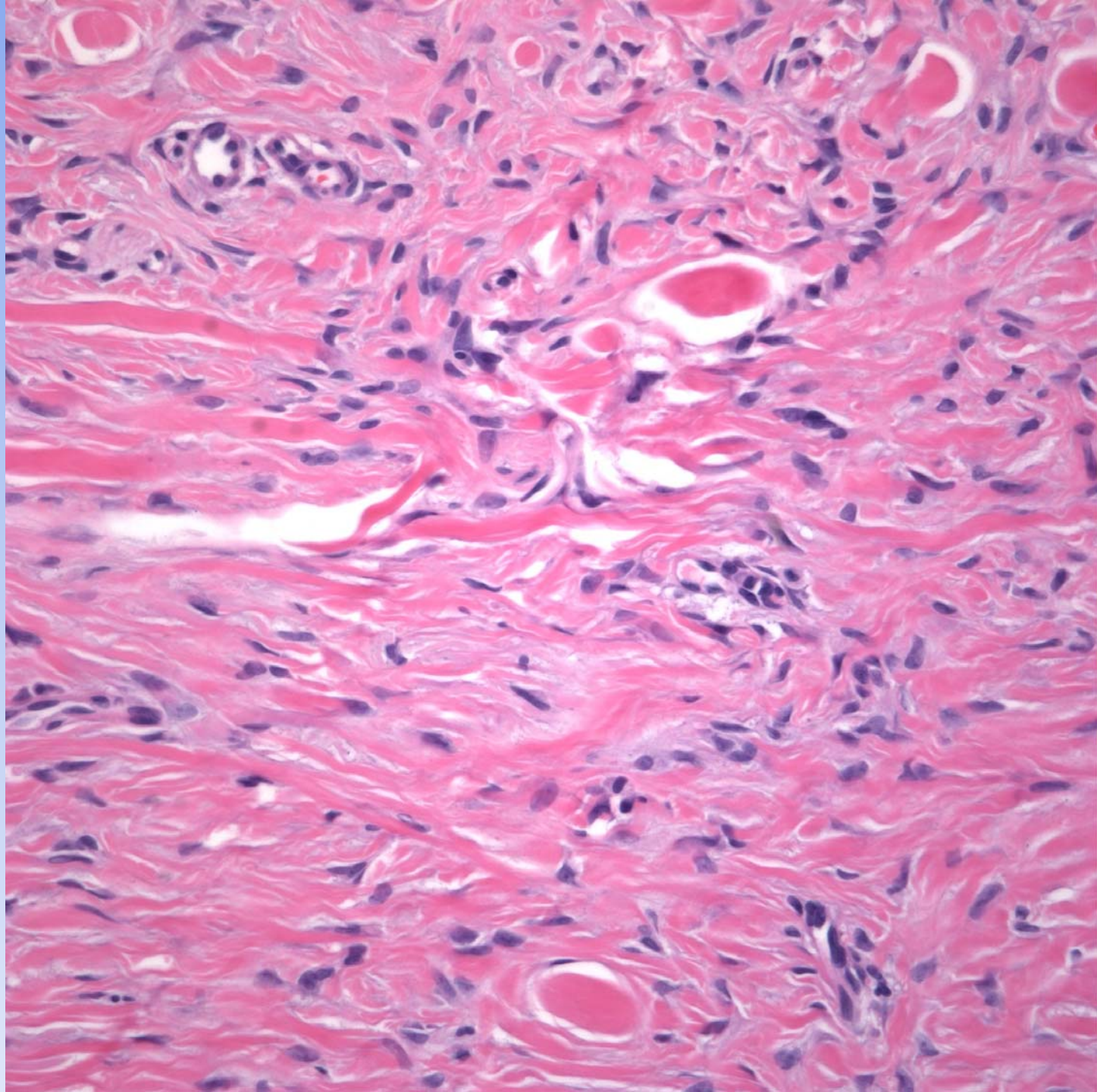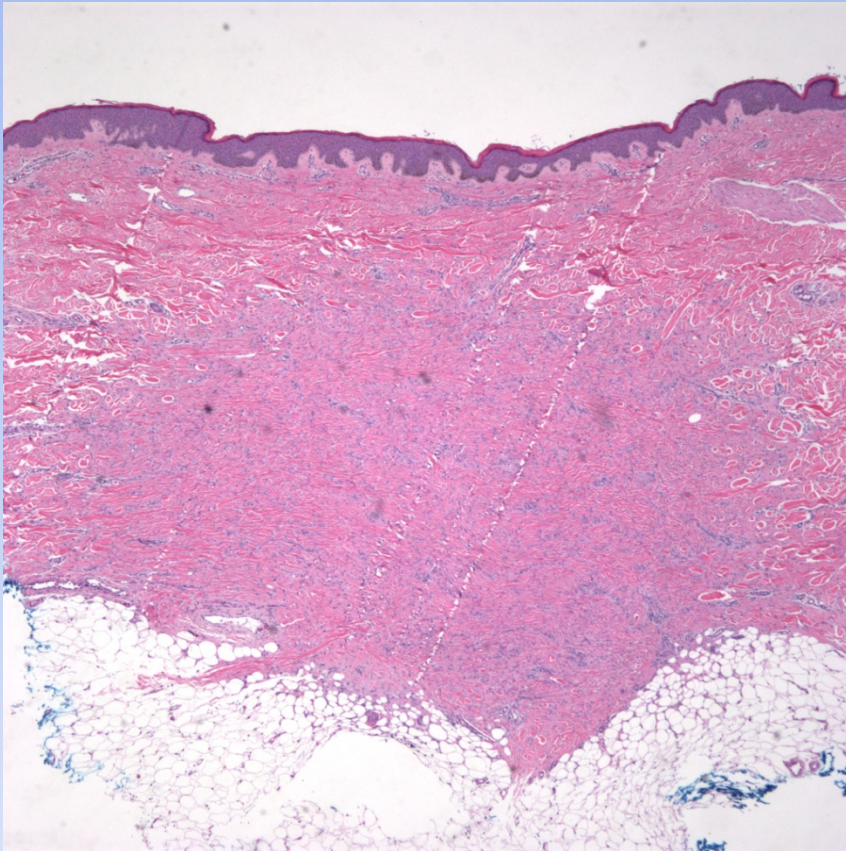


Dermatofibroma

Pearls



- Cellular “blue nodule” in dermis
- Epidermis hyperplastic with “dirty fingers” of hyperpigmented rete ridges
- Dell-like depression in some cases (Fitzpatrick sign)
- Rootlike extension of spindle cells into subQ fat